

In-Situ Split Calvarial Bone Graft for Reconstruction of Cranial Bone Defect

TAREK ELBANOBY, M.D.

The Department of Plastic and Reconstructive Surgery, Faculty of Medicine, Al-Azhar University

ABSTRACT

Patients and Methods: This article presents the long-term results of skull defect reconstruction in a series of 13 patients studied between 2011 and 2013 (mean age, 34 yr; range, 18-50 yr). Causes of their defects were trauma (ten patients), tumor (two patients) and brain abscess (one patient). All patients underwent clinical and computed tomographic scan documentation of their skull defects before and immediately after surgery and at least 1 year later. The average preoperative defect surface area measured 2.1 x 4 cm².

Results: Skull defects were reconstructed in all patients with in-situ split calvarial bone grafts, they were fixed with a microplates and screws. Follow-up ranged from 12 to 60 months (mean, 31.4 mo). Complications were minimal, with only one case of infection but no plate or graft exposure, or intracranial injuries. In all patients, clinical examination and computed tomographic scans showed no evidence of skull defect or appreciable irregularity of donor or recipient sites. All patients have resumed routine activities without special head protection.

Conclusion: Repair of skull defects with in-situ split calvarial bone grafts is a reliable autogenous method of reconstruction with minimal morbidity.

Key Words: *In situ split – Calvarial – Bone graft – Reconstruction cranial.*

INTRODUCTION

Repair of large and complex cranial defects remains a special challenge for reconstruction. The main objective is to achieve functional and cosmetic reconstruction using a biomechanically and biochemically reliable material [1]. Calvarial bone graft has been considered the criterion standard for skull reconstruction [2].

In this study, we examined 13 patients with large calvarial defects who underwent cranioplasty with in situ splitted calvarial bone graft. We ob-

served these patients for up to four years after the procedure, and assess the outcome of it.

PATIENTS AND METHODS

Between 2011 and 2013, 13 patients (10 men and 3 women) underwent cranioplasty with in situ splitted calvarial bone graft due to a posttraumatic non restorable large skull defect, lysis, or infection of the bone flap after severe head trauma (10 patients); meningioma (2 patients); and brain abscess (1 patient). Some relevant clinical data are presented in Table (1). A follow-up evaluation of all patients confirmed good clinical and cosmetic results in all cases. Preoperative and postoperative CT scans were done to all patients with evaluation of the reconstruction of both the cranial vault defect and the donor site.

Surgical technique:

After determination of size of the cranial defect, a bicoronal incision is planned, the area is injected with 1% lidocaine mixed with 1: 100,000 units of epinephrine and is sterilely prepped with Betadine. Following the incision, the scalp is elevated in a plane above pericranium. The next step is resection of the in-situ splitted calvarial bone graft with Tessier method [3].

We gently trace the outline of the donor site and all strips of bone with an L-shaped oscillating saw. Then we burr Deeply down into the diploe all the furrows delineating the bone grafts, using cutting burr. With the use of curved osteotome. The splitting is made segment after segment with 7-, 10-, or 15-mm wide, sharp osteotomes, alternating straight or curved osteotomes, depending on the depth, direction, and feeling. After all the main segments have been removed, sheets of diploe are taken with a straight

osteotome, down to the inner table. The parietal bone can provide as much bone as an iliac wing. After bleeding has been controlled, any excess bone wax is removed by scraping with a sharp elevator.

Closure: The donor site is covered with large pieces of Surgicel and a Hemovac drain is brought out through the posterior portion of the incision. The pericranium is sutured over the donor site, the galea is closed, and the scalp is approximated with sutures or staples.

Restoration of the cranial defect with the bone graft and fixation with titanium microplates with self-tapping screws were used (Figs. 2,3,5).

RESULTS

Thirteen patients have had in-situ split calvarial bone graft for skull reconstruction. The patient's profile is provided in Table (1). The median post-operative follow-up was 3.3 years (range: 2-5

years). The main site of surgery was the frontal bone in 61.5% of cases, followed by temporal bone in 38.5%. The mean size of the defect was 2.1 x 4cm. Only two cases presented a complication, consisting of infection in one case and slight bone resorption in the 2nd case. These complications were managed by drainage and fat injection, respectively. Apart from those two cases, there were no perioperative infections, incidence of bone plate exposures, or intracranial injuries in any of the patients. The operation time ranged from 90 to 190 minutes (mean 118 minutes).

None of the implanted titanium plates had to be removed. CT scans were done soon after surgery and six months post-operative showed complete healing of bone grafts and the thickness of the reconstructed bone appeared similar to that of the surrounding bone in the majority of patients. All patients have resumed routine activities without special head protection (Figs. 1,4).

Table (1): Demographic data of the patients, including the etiology, site and size of the defects with the additional procedure operated.

| No. | Sex | Age | Cause | Site of defect | Size of defect | Added procedures | Complications | 2ry procedures |
|-----|--------|-----|---------------|----------------|----------------|---|-----------------|-----------------------------|
| 1 | Female | 28 | Trauma | Frontal | 4x5 | Canthoplasty and orbital rim reconstruction by iliac bone graft | | |
| 2 | Male | 26 | Trauma | Temporal | 5x7 | None | | |
| 3 | Male | 44 | Trauma | Frontal | 2x4 | Cranialization | | |
| 4 | Male | 21 | Truma | Frontal | 2x3 | Cranialization and canthoplasty | | |
| 5 | Male | 47 | Trauma | Frontal | 3x4 | Cranialization and sinus obliteration by galeal flap | | |
| 6 | Female | 43 | Meningioma | Temporal | 4x7 | None | | |
| 7 | Male | 18 | Trauma | Frontal | 3x3 | None | Infection | Drainage-sinus obliteration |
| 8 | Male | 47 | Meningioma | Temporal | 4x6 | None | | |
| 9 | Male | 50 | Trauma | Temporal | 4x5 | None | | |
| 10 | Female | 44 | Trauma | Frontal | 3x3 | Sinus obliteration by galeal flap | | |
| 11 | Male | 22 | Brain abscess | Temporal | 3x3.5 | None | Bone resorption | Fat transfer |
| 12 | Male | 38 | Trauma | Frontal | 3x4 | Cranialization | | |
| 13 | Male | 26 | Trauma | Frontal | 3.5x2.8 | None | | |

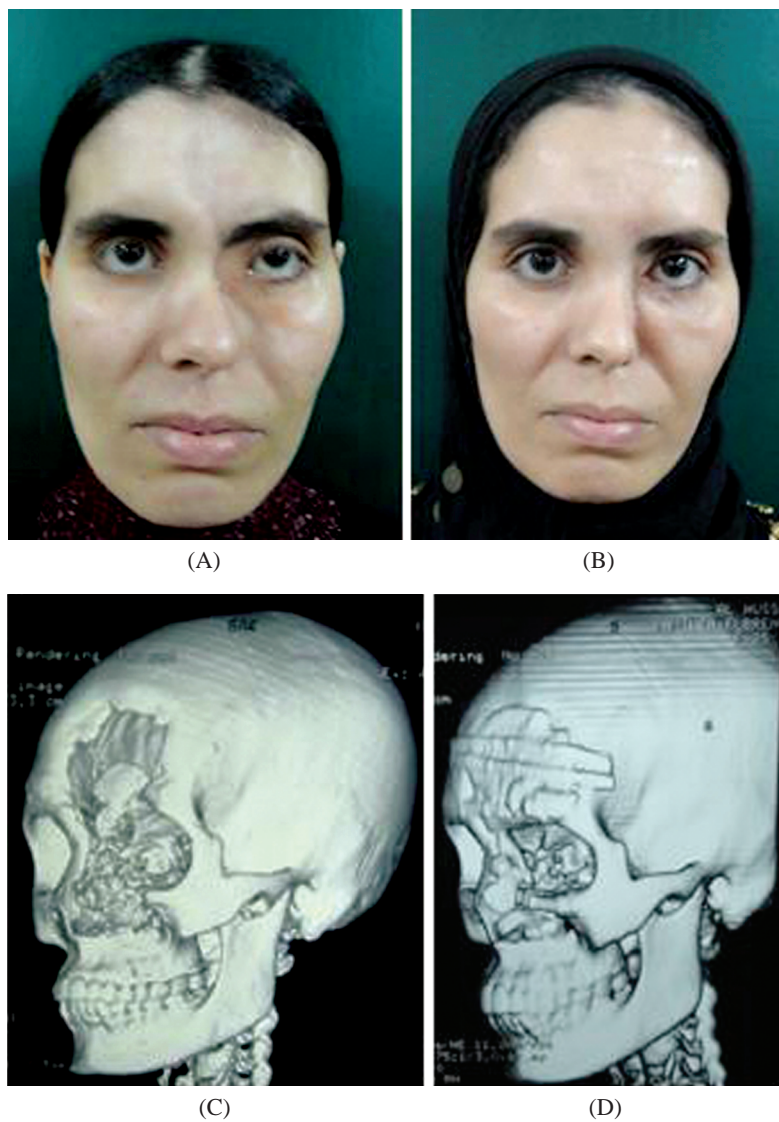

Fig. (1): (A & B): Female patient 28 years with posttraumatic frontal bone defect pre and postoperative.
(C & D): 3D CT scan pre and postoperative.

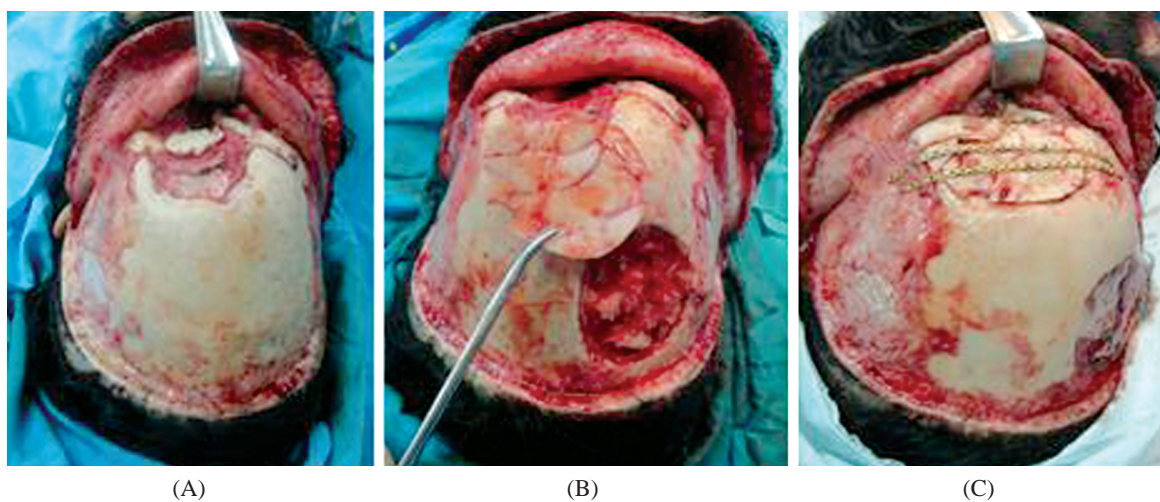


Fig. (2): (A): After coronal approach with exposure of the frontal bone defect.
(B): Clavierian bone graft after harvest.
(C): Fixation of the clavierian bone graft with miniplates and screws.

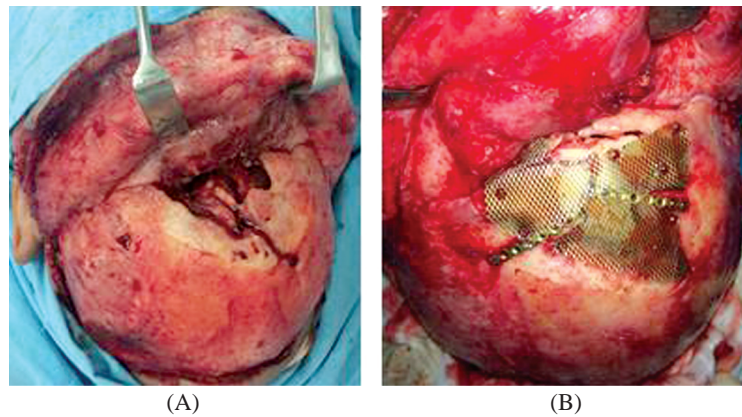


Fig. (3): (A): After exposure of frontal bone defect through coronal approach
(B): Claverian bone graft fixation by Titanium mesh, plates and screws.

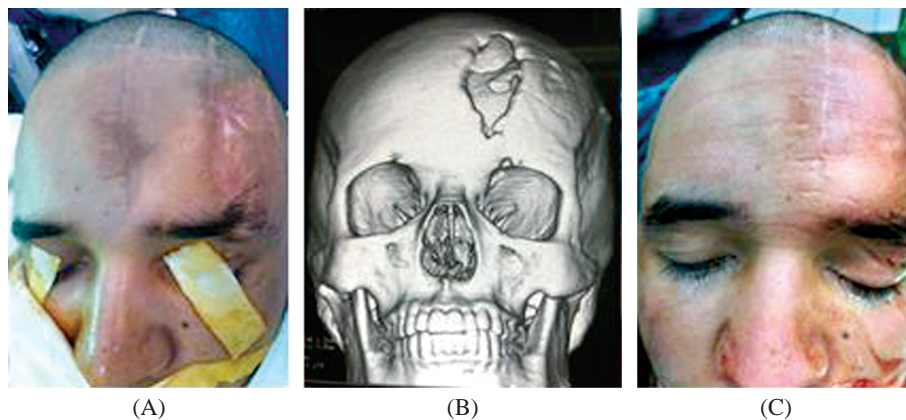


Fig. (4): (A): Male patient 18 Years with Preoperative posttraumatic frontal bone defect .
(B): 3D CT scan showing the frontal bone defect.
(C): Immediate postoperative view after reconstruction of the frontal bone defect.

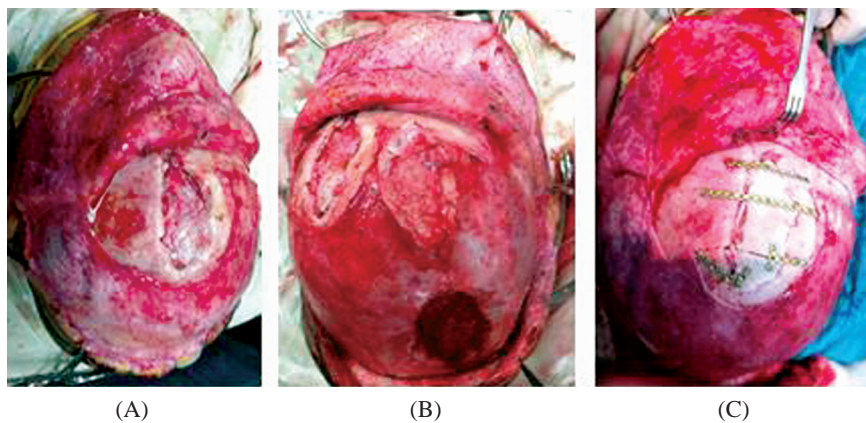


Fig. (5): (A): The same patient in Fig. (4) after exposure of the frontal bone defect by coronal approach.
(B): Claverian bone graft after being harvested in situ.
(C): Fixation of the Claverian bone graft by plates and screws.

DISCUSSION

A successful cranioplasty should provide functional protection, a satisfactory cranial vault contour, and acceptable levels of morbidity [4]. There is evidence that cranioplasty have been performed

by several early cultures like Pre-Columbian Incus and Europe during the renaissance using gold or silver plates with various degree of success [5]. However, the first reported cranioplasty was probably that of a Russian Nobleman, with a piece of dog's cranium [6]. Numerous techniques have been

reported, advocating a spectrum of alloplastic or autogenous sources of reconstructive material [7,8]. In general, repair with alloplasts offers the advantages of malleability, easy accessibility, durability, and avoidance of the need for an autogenous donor site. However, Allografts have the risk of immunological reactions and contamination [9,10].

The main objective of cranioplasty is to achieve functional and cosmetic reconstruction using a biomechanically and biochemically reliable material. Autologous bone remains the preferred option because of its potential growth and replacement of host cells. The most common donor areas for autogenous bone graft are the cranium, iliac bone, and ribs. Calvarian Grafts become vascularized and osseointegrate with surrounding bone, and thus infection, dislodgement, or breakdown are minimized [1,2,9].

Cranial bone is our preferred grafting material because a remote donor site is not required, there is less donor-site morbidity compared with harvesting rib or iliac bone; and cranial graft has better volume maintenance than rib or iliac bone.

Many studies have reported no resorption and no loss of calvarial transplants after repair, on a short-term follow-up, ranging from 1 to 3.7 years [11].

The disadvantages regarding cranial bone is that there is a limited amount that can be harvested, particularly in young children and when the defect is adjacent to the graft donor site. This perception is one reason why endochondral bone and/or alloplastic materials are often used for craniofacial reconstruction.

Another disadvantage of calvarial grafts is the risk of violating the inner table or dura during harvest [12]. But in our series, we overcome these obstacles with the in-situ splitting of the bone graft, which allowed us to harvest a large surface area of bone without risks of injured the dura.

In our series, cranial vault defects were successfully reconstructed with fixed cranial bone grafts with a mean follow-up of more than 2.5 years. No patient developed an infection, hematoma, plate exposure, or intracranial injury apart from single case with infection and other with slight resorption which were managed conservatively.

Conclusion:

Reconstruction of a cranial vault defect is often warranted for protective and functional reasons as well as for aesthetic concerns. The in-situ split calvarial bone graft is proved to be a reliable and safe method for restoration of cranial defects.

REFERENCES

- 1- Tessier P.: Autogenous bone grafts taken from the calvarium for facial and cranial applications. Clin. Plast. Surg., 9: 531-538, 1982.
- 2- Tessier P., Kawamoto H., Matthews D., et al.: Autologous bone grafts and bone substitutes tools and techniques: I. A 20,000-case experience in maxillofacial and craniofacial surgery. Plast. Reconstr. Surg., 116: 92S-94S, 2005.
- 3- Tessier P., Kawamoto H., Posnick J., et al.: Taking calvarial grafts, either split in situ or splitting of the parietal bone flap ex vivo tools and techniques: V. A 9650-case experience in craniofacial and maxillofacial surgery. Plastic and Reconstructive Surgery, Oct 1; 116 (5): 54S-71S, 2005.
- 4- Posnick J.C., Goldstein J.A., Armstrong D., et al.: Reconstruction of Skull Defects in Children and Adolescents by the Use of Fixed Cranial Bone Grafts: Long-Term Results. Neurosurgery, May 1; 32 (5): 785-91, 1993.
- 5- Sanan A. and Haines S.J.: Repairing holes in the head: A history of cranioplasty. Neurosurgery, 40: 588-603, 1997.
- 6- Amit Agrawal and Lakshmi N. Garg: Split Calvarial Bone Graft for the Reconstruction of Skull Defects: Journal of Surgical Technique and Case Report, Jan-Jun, Vol-3, Issue-1, 2011.
- 7- Marchac D.: Deformities of the forehead, scalp, and cranial vault, in McCarthy J.G. (ed): Plastic Surgery. Philadelphia, Saunders, pp 1538-1573, 1990.
- 8- Parsons R.: Partial skull loss-alloplastic cranioplasty, in Stark R.B. (ed): Plastic Surgery of the Head and Neck. New York, Churchill Livingstone, Vol 1, pp 60-64, 1987.
- 9- Gary F.: Rogers et al. Autogenous Bone Graft: Basic Science and Clinical Implications. J. Craniofac. Surg., 23: 323Y327, 2012.
- 10- Andrea, et al.: Clinical Outcome in Cranioplasty: Critical Review in Long-Term Follow-up, Presented at the 13th Annual Meeting of the North American Skull Base Society, San Diego, CA, February 16-19, 2002.
- 11- Rogers G.F., Greene A.K., Mulliken J.B., et al.: Exchange cranioplasty using autologous calvarial particulate bone graft effectively repairs large cranial defects. Plast. Reconstr. Surg., 127:1631Y1642, 2011.
- 12- Earley M.J., Green M.F. and Milling M.A.: A critical appraisal of the use of free flaps in primary reconstruction of combined scalp and calvarial cancer defects. Br. J. Plast. Surg., 43: 283-9, 1990.